



Small aperture IC-8 intraocular lens in cataract patients: achieving extended depth of focus through small aperture optics

Joobin Hooshmand¹ · Penny Allen^{1,2} · Tess Huynh³ · Christopher Chan⁴ · Ravi Singh⁵ · Con Moshegov⁶ · Smita Agarwal⁷ · Erin Thornell⁷ · Brendan J. Vote¹

Received: 9 August 2018 / Revised: 29 November 2018 / Accepted: 13 January 2019 / Published online: 19 February 2019
© The Royal College of Ophthalmologists 2019

Abstract

Background To investigate visual outcomes following cataract surgery in patients who were implanted monocularly with an extended range of focus IC-8 IOL.

Methods A multicentre, non-randomised, retrospective case series of 126 consecutive patients implanted with the IC-8 IOL. Data were collected and pooled from six centres across Australia. Uncorrected distance visual acuity (UDVA), uncorrected intermediate visual acuity (UIVA) at 80 cm and uncorrected near visual acuity (UNVA) at 40 cm were measured in eyes implanted with the IC-8 IOL. Adverse events, spectacle independence, visual symptoms and patient satisfaction were assessed at final follow-up.

Results Over 90% of the patients without pre-existing ocular pathology ($n = 109$) achieved UDVA, UIVA and UNVA of 6/12 or better in the IC-8 eye. Binocularly, in this group, 98% achieved UDVA of 6/9, 94% UIVA of 6/12 and 91% UNVA of 6/12 or better. By final follow-up, over 50% of patients reported complete spectacle independence for distance, intermediate and near visual activity, with the remainder only using spectacles for specific tasks such as near-vision hobbies and reading in dim light.

Conclusions The IC-8 IOL is capable of providing extended depth of focus following cataract surgery. It allows complete spectacle independence in more than half of the patients implanted with the IC-8 IOL.

Introduction

Recent advances in intraocular lens (IOL) technology and design have made complete spectacle independence following cataract surgery well within reach. Multifocal IOLs have achieved significant progress in this arena by

providing improved near and/or intermediate visual acuity (VA) when compared with standard monofocal lenses [1–3]. However, this has come at the expense of reduced optical quality inherent in the light splitting design of these IOLs for distance and intermediate and near foci. Multifocal IOLs are also associated with high rates of adverse effects ranging from decreased contrast sensitivity to glare and halos [3–5]. More recently, single optic ‘accommodating’ IOLs designed to allow movement along the visual axis by using the action of ciliary muscle have been reported to make mild to moderate improvements in depth of focus post cataract surgery without loss of optical quality when compared with monofocal lenses [6, 7]. However, these IOLs are limited by their low and variable amplitude of ‘accommodation’ and rely on forward translation or induced spherical aberration rather than dynamic changes in refractive index [8]. Small aperture optics is another promising technology in the quest to achieve extended range of focus post cataract surgery and is further discussed below along with an initial clinical evaluation of its performance.

✉ Joobin Hooshmand
joobin.hooshmand@gmail.com

¹ Tasmanian Eye Institute, 36 Thistle St West, South Launceston, TAS 7249, Australia
² Rural Clinical School, University of Tasmania, Burnie, TAS 7320, Australia
³ iVision Clinic Inner West, Sydney, NSW, Australia
⁴ North West Eye Specialists, Melbourne, VIC, Australia
⁵ Eye Specialists Group, Newcastle, NSW, Australia
⁶ George Street Eye Centre, Sydney, NSW, Australia
⁷ Wollongong Eye Specialists, Wollongong, NSW, Australia

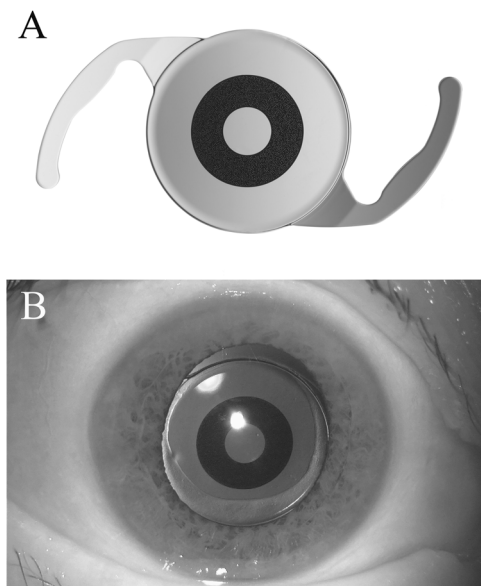


Fig. 1 **a** The IC-8 intraocular lens (IOL). **b** The IC-8 IOL viewed through a dilated pupil

The IC-8 (AcuFocus Inc., California, USA) is a single piece hydrophobic acrylic posterior chamber IOL which combines small aperture optics with a monofocal IOL to achieve extended depth of focus. The IOL is embedded with a central 3.23 mm black circular mask composed of polyvinylidene difluoride and carbon nano-particles at the centre of which lies a 1.36 mm non-diffractive clear circular aperture (Fig. 1a). The IOL has a 6.00 mm optic diameter with an overall diameter of 12.5 mm. The mask has over 3200 micro-perforations, each 5 μ m in thickness. The IOL is available in +15.5 to +27.5 dioptre (D) range with an A-constant of 120.5.

The IC-8 design is based on the KAMRA corneal inlay (AcuFocus Inc., California, USA) which utilises similar small aperture optics [9]. The small aperture KAMRA corneal inlay is used for the correction of presbyopia in phakic and pseudophakic eyes and has been shown to increase depth of focus and improve near and intermediate visual acuities with minimal or no impact on distance VA [10–12]. The KAMRA inlay is also associated with better contrast sensitivity when compared with multifocal and ‘accommodative’ IOLs [10]. Though rare, serious complications such as infectious keratitis, stromal scarring, corneal epithelisation and haze have been reported in the literature and thereby limit the corneal inlay’s clinical utility [13–15]. The new IOL-based small aperture optics technology is a significant step in resolving issues experienced with the KAMRA corneal inlay and provides greater access to cataract patients in a simplified single procedure (Fig. 1b). We report on the visual outcomes of 126 patients who underwent IC-8 IOL implantation including 17 with significant pre-existing ocular comorbidity.

Materials and methods

A retrospective, non-randomised, clinical case series was carried out on data collected and pooled from 6 centres across Australia that utilise the IC-8 IOL. The study was conducted in accordance with the tenants of the Declaration of Helsinki and approved by the University of Tasmania Human Research Ethics Committee (H0016646). Informed consent was obtained from all participants. All subjects underwent cataract extraction by standard phacoemulsification (PCS) and were implanted with IC-8 IOL in one eye (usually the non-dominant eye). IOL selection for the fellow eye, if required, was based on the surgeon’s assessment and preference. The IC-8 IOL target refraction was -0.75 , based on the company recommendation; the target refraction for the fellow eye was emmetropia. Patients were followed up with post-operative visits at day 1, week 2 and beyond as clinically indicated with a final follow-up arranged for the purpose of comprehensive visual acuity and satisfaction assessment.

IC-8 patient selection criteria

The IC-8 IOL was considered in patients who expressed a desire to achieve reduced spectacle dependence following cataract surgery, or in patients with corneal scarring but a clear central visual axis. If cataract was present in both eyes, usually the non-dominant eye was chosen for the IC-8 IOL and implanted after uncomplicated cataract surgery in the fellow eye. Pre-operative corneal astigmatism of up to 1.5 D was considered acceptable for the implant eye; those needing a toric lens for more than 1.5 D of astigmatism were generally excluded. A late exclusion criterion was a pupil size of greater than 6 mm and this will be discussed in more detail. Unless the central visual axis was obscured, patients with pre-existing ocular pathology were deemed eligible and considered for IC-8 implant based on the above selection criteria.

Pre-operative assessment

Routine baseline cataract workup was carried out for all patients including measurement of corrected distance visual acuity (CDVA) and uncorrected distance visual acuity (UDVA), intraocular pressure (IOP), manifest refractive spherical equivalence (MRSE), optical biometry, slit lamp and dilated fundus examination.

Operative technique

All patients underwent standard PCS surgery. The IC-8 IOL was inserted via the specifically designed injector system

which is capable of delivering the IOL through a 3.5 mm corneal incision.

Post-operative assessment

Uncorrected distance visual acuity (UDVA), uncorrected intermediate visual acuity (UIVA) at 80 cm and uncorrected near visual acuity (UNVA) at 40 cm were measured at each follow-up visit using the Snellen chart for distance and Jaeger eye chart for near and intermediate visual acuities. These were later converted to logarithm of the minimum angle of resolution (logMAR) for the purpose of analysis and reporting. The post-operative assessment also included slit lamp bio-microscopy and dilated fundus examination.

At the final follow-up visit, all patients were asked to rate their dependence on glasses for reading and distance vision on a scale of 0–10, with 0 indicating no need for glasses and 10 indicating complete dependence. Similarly, satisfaction with near and distance vision was assessed using a scale of 0–10, with 0 indicating not satisfied and 10 indicating extreme satisfaction. Symptoms including blurry or fluctuating vision, distortion, dryness, glare, halos, night vision problems, pain or burning sensation and diplopia were also assessed on a scale of 0–10, with 0 indicating no symptoms and 10 indicating severe symptoms. Finally, patients were asked if they would recommend the IC-8 lens to their family and friends.

Data analysis

Data extracted from the patient management database were imported into Stata 14 (Stata Data Analysis and Statistical Software Stata Corp LLC, Texas USA) for descriptive analysis. Those with no pre-existing ocular comorbidity were grouped together for the purpose of analysis and reporting ($n = 109$). Other than for demographic purposes, the patients with pre-existing ocular comorbidity ($n = 17$) were analysed and reported separately. Means, standard deviations and confidence intervals were calculated for visual acuity (logMAR). Mean visual acuity (logMAR) at follow-up compared to baseline was investigated.

Results

Table 1 describes the demographics and ocular characteristics of all patients included in this study. Sixty-four male (50.8%) and 62 females (49.2%) were implanted with the IC-8 IOL. Age ranged from 43 to 89 years with a mean of 68 years (SD 8.8). Fifty right (39.7%) and 76 left (60.3%) eyes were implanted with the IC-8. In the fellow eye, 19 patients did not require cataract surgery, 52 received a monofocal, 35 a toric monofocal and 19 a multifocal IOL.

Table 1 Baseline demographics of patients and pre-operative characteristics of the IC-8-implanted eyes

Baseline characteristic	Mean (SD)	Range	95% Confidence interval
Age (years)	68 (8.8)	43–89	66.2, 69.3
Gender (female)	62 (49.2%)	–	–
MRSE (D)	0.60 (2.49)	–10.50 to 9.00	0.15, 1.05
Sphere (D)	0.24 (2.63)	–10.75 to 12.00	–0.24, 0.71
Cylinder (D)	0.76 (0.96)	0.00–6.00	0.59, 0.93

D dioptres, *MRSE* manifest refractive spherical equivalent

One patient with extensive corneal scarring but a clear central visual axis received IC-8 IOL in both eyes. Six patients did not attend the final follow-up visit. The mean follow-up duration was 29 weeks (SD 19.8) (range 1 to 75 weeks).

Baseline pre-operative distance visual acuity in the IC-8 and fellow eye of the patients without pre-existing comorbidity as well as the post-operative UNVA, UIVA and UDVA are demonstrated in Table 2a. Table 2b demonstrates the baseline and the post-operative visual acuities achieved in patients with pre-existing ocular pathology.

Over 90% of the 109 patients without pre-existing ocular pathology achieved UDVA, UIVA and UNVA of 6/12 or better in the IC-8 eye; mean logMAR VA was 0.13 (SD 0.16), 0.10 (SD 0.19) and 0.18 (SD 0.17) respectively. Binocularly, in this group, 98% achieved UDVA of 6/9, 94% UIVA of 6/12 and 91% UNVA of 6/12 or better; mean binocular logMAR VA was 0.00 (SD 0.10), 0.1 (SD 0.18) and 0.20 (SD 0.12) respectively. Figure 2a, b demonstrates the cumulative percentage of patients achieving monocular and binocular target visual acuity at the final post-operative visit.

Patient questionnaire

A patient satisfaction questionnaire was completed by 102 patients (81%) (Table 3). Overall, 55 patients (54%) reported spectacle independence for reading and 93 (91%) for distance visual activity following IC-8 IOL implantation. Among those dependent on spectacles for reading, the degree of dependence ranged from 1 to 10 with a mean of 5.6 (SD 2.6). For the nine patients who expressed dependence on spectacles for distance vision, the degree of dependence ranged from 1 to 10 with a mean of 5.4 (SD 3.4).

Patients ranked their satisfaction with near vision a mean of 8.1 out of 10 (SD 2.7). Satisfaction with distance vision was ranked a mean of 9.1 out of 10 (SD 1.6). Eighty-six (84%) patients were happy to recommend the IC-8, 5 patients (5%) were 'not sure', 7 indicated that they would

Table 2a Baseline and post-operative monocular and binocular visual acuities in patients with no pre-existing ocular pathology

Visual acuity	Snellen, logMAR mean (SD)	Range	Confidence interval
Baseline monocular VA			
UDVA ^a (IC-8)	[6/12] 0.31 (0.25)	[6/5] -0.09, 1.10 [6/75]	0.28, 0.38
BDVA ^a (IC-8)	[6/9] 0.17 (0.17)	[6/4] -0.18, 1.00 [6/60]	0.14, 0.20
UDVA ^a (fellow eye)	[6/12] 0.28 (0.27)	[6/3] -0.30, 1.20 [6/95]	0.23, 0.33
BDVA ^a (fellow eye)	[6/7.5] 0.14 (0.15)	[6/6] -0.3, 0.60 [6/24]	0.11, 0.16
Post-operative IC-8 eye VA			
UNVA ^b	[6/9] 0.18 (0.17)	[6/6] 0.00, 0.70 [6/30]	0.15, 0.22
UIVA ^b	[6/7.5] 0.10 (0.19)	[6/4] -0.18, 0.70 [6/30]	0.06, 0.14
UDVA ^a	[6/7.5] 0.13 (0.16)	[6/4] -0.18, 0.60 [6/24]	0.10, 0.16
Post-operative binocular VA			
UNVA ^b	[6/9.5] 0.20 (0.12)	[6/7.5] 0.10, 0.70 [6/30]	0.18, 0.22
UIVA ^b	[6/7.5] 0.07 (0.18)	[6/4] -0.18, 0.71 [6/30]	0.03, 0.10
UDVA ^a	[6/6] 0.00 (0.10)	[6/4] -0.18, 0.30 [6/12]	-0.02, 0.02

[Snellen]; logMAR (SD)

LogMAR logarithm of the minimum angle of resolution, VA visual acuity, UDVA uncorrected distance visual acuity, BDVA best-corrected distance visual acuity, UIVA uncorrected intermediate visual acuity, UNVA uncorrected near visual acuity

^aLogMAR

^bLogMAR converted from Jaeger near vision

Table 2b Baseline and post-operative monocular and binocular visual acuities in patients with pre-existing ocular pathology

Comorbidity	Eye	Baseline			Follow-up	
		BDVA ^a	UDVA ^a	UDVA ^a	UIVA ^b	UNVA ^b
Corneal scarring (6)	IC-8	[6/9.6] 0.26	[6/15] 0.45	[6/15] 0.46	[6/12] 0.36	[6/12] 0.35
	Fellow	[6/7.5] 0.10	[6/12] 0.31	[6/7.5] 0.14	[6/9] 0.17	[6/15] 0.47
Post Lasik (4)	IC-8	[6/9.6] 0.24	[6/19] 0.49	[6/7.5] 0.10	[6/4.8] -0.10	[6/7.5] 0.08
	Fellow	[6/9] 0.18	[6/9.5] 0.20	[6/7.5] 0.08	[6/4.8] -0.10	[6/9] 0.17
Glaucoma (2)	IC-8	[6/15] 0.36	[6/21] 0.54	[6/9.6] 0.25	[6/9.5] 0.20	[6/12] 0.35
	Fellow	[6/9.6] 0.25	[6/15] 0.45	[6/9.5] 0.20	[6/9.5] 0.20	[6/12] 0.35
CME and ERM (1)	IC-8	[6/9.6] 0.24	[6/15] 0.40	[6/12] 0.30	[6/15] 0.40	[6/6] 0.00
	Fellow	[6/9.6] 0.24	[6/9.6] 0.24	[6/4] -0.18	[6/15] 0.40	[6/12-2] 0.50
Amblyopia (1)	IC-8	[6/12] 0.30	[6/12] 0.30	[6/15] 0.40	[6/15] 0.40	[6/15] 0.40
	Fellow	[6/7.5] 0.10	[6/7.5] 0.10	[6/7.5] 0.10	NA	NA
Keratoconus (1)	IC-8	[6/24] 0.60	[6/46] 0.88	[6/38] 0.80	[6/38] 0.80	[6/19] 0.50
	Fellow	[6/6] 0.00	[6/6] 0.00	[6/6] 0.00	[6/12] 0.30	[6/24] 0.60
NPDR (1)	IC-8	[6/9.6] 0.24	[6/9.6] 0.24	[6/12] 0.30	[6/7.5] 0.10	[6/12] 0.30
	Fellow	[6/9.6] 0.24	[6/9.6] 0.24	[6/7.5] 0.10	[6/15] 0.40	[6/30] 0.70
CNVM (1)	IC-8	[6/12] 0.30	[6/19] 0.50	[6/15] 0.40	[6/15] 0.40	[6/19] 0.50
	Fellow	[6/15] 0.40	[6/15] 0.40	[6/15] 0.40	[6/12] 0.30	[6/15] 0.40

(Number of patients); [Snellen]; logMAR

LogMAR logarithm of the minimum angle of resolution, UDVA uncorrected distance visual acuity, BDVA best-corrected distance visual acuity, UIVA uncorrected intermediate visual acuity, UNVA uncorrected near visual acuity, NA not available, NPDR nonproliferative diabetic retinopathy, CNVM choroidal neovascular membrane

^aLogMARs

^bLogMAR converted from Jaeger near vision

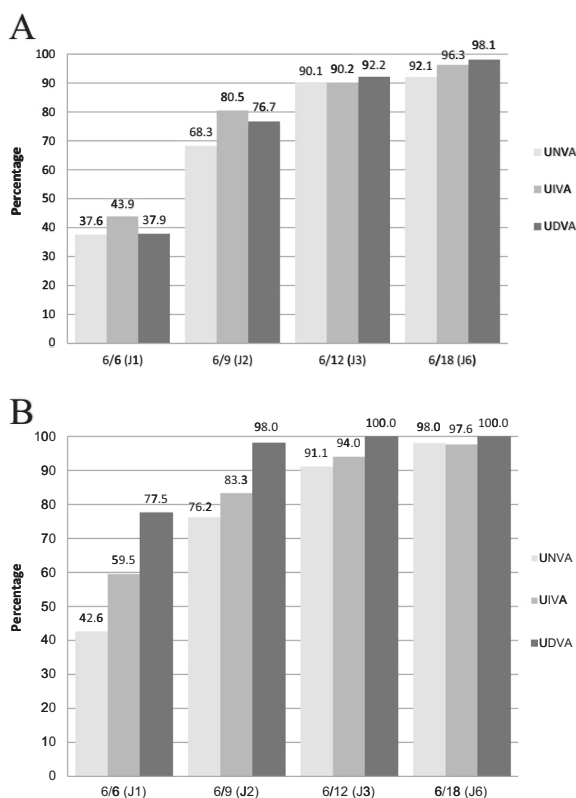


Fig. 2 Cumulative percentage of patients achieving uncorrected near (UNVA), intermediate (UIVA) and distance (UDVA) target acuity **a** monocularly in the IC-8 implanted eye. **b** Binocularly with IC-8 in one eye

Table 3 Summary of binocular symptoms reported by patients at the final follow-up and associated severity

Symptom	Number (percentage)	Mean (SD)	Range
Blurred/fluctuating vision	54 (53%)	4.6 (2.5)	1–10
Distortion	11 (11%)	4.7 (2.6)	2–10
Dryness	44 (43%)	4.8 (2.2)	1–4
Glare	51 (50%)	5.6 (2.5)	1–10
Halos	43 (42%)	5.4 (2.7)	1–10
Night-time visual problems	27 (26%)	6.6 (2.6)	1–10
Pain/burning sensation	11 (11%)	3.2 (1.7)	1–6
Diplopia	12 (12%)	5.7 (2.8)	1–10

SD standard deviation

not recommend the IC-8 (7%) and 4 patients did not respond to this question (4%).

Adverse events

IOL explant and exchange occurred in 7 patients (5.5%). The majority of cases were attributed to poor VA subsequent to early posterior capsule opacity (PCO) and

uncertainty around the ability to perform Nd:YAG (neodymium-doped yttrium aluminium garnet) laser posterior capsulotomy through the IC-8. One patient was noted to have difficulty adjusting to the difference between the two eyes and one patient had an IOL exchange with a monofocal IOL due to large floaters following posterior vitreous detachment. That patient failed to notice any improvement in symptoms post IOL exchange.

Discussion


The IC-8 shows superior depth of focus in near and intermediate visual acuity compared to monofocal and accommodative IOLs and slightly better or comparable results to that of multifocal IOLs [15–17]. The strength of the IC-8 IOL in delivering good spectacle independence comes from the combination of:

1. Targeting a small amount of monovision ('mini-monovision' of approximately -0.75 D) in the IC-8 IOL eye coupled with monofocal IOL in the fellow eye aiming for emmetropia.
2. The extended range of depth of focus for the IC-8 IOL (especially in photopic conditions).

The 'pinhole' design of the optic in the IC-8 allows for high-quality images across an extended dioptric range (approximately 2 to 2.25 D). The International Organisation for Standardisation (ISO) standard bench testing by the pilot group demonstrated this through a series of focus image data measured at 0.25 D incremental steps (Fig. 3a). Such an extended range of depth of focus makes the IC-8 particularly forgiving when targeting refractive endpoints. The IC-8 high image quality (high modulation transfer function) is also comparable to monofocal IOLs. However, monofocal IOLs typically provide only about 0.75 D of range in depth of focus (Fig. 3b). As such, we believe the IC-8 is particularly suited to achieving greater tolerance of targeting spectacle independence through monovision.

There are few drawbacks clinically, with only a small number of patients having lasting adverse visual effects often experienced by those with multifocal IOLs [3–5]. Any dysphotopic symptoms experienced were transient and usually resolved with adaptation. Cylinder defocus testing of the IC-8 in 0.5 D increments demonstrates no reduction in logMAR or Snellen acuity with up to 1.5 D of astigmatism. Thus, an eye with an IC-8 should be capable of tolerating up to 1.5 D of uncorrected astigmatism (Fig. 3c). The utility of the IC-8 IOL in the context of astigmatism was particularly evident in one patient with keratoconus. With 4.25 D of corneal cylinder and an UNVA of 6/19 post-operatively, the patient was 'delighted' with the functional

Fig. 3 **a** IC-8 intraocular lens (IOL) optical image focus quality measured at 0.25 D increments in ISO model eye in white light (halogen 440–755 nm) (dioptric range ~2 to 2.25 D). **b** Tecnis monofocal IOL optical image focus quality measured under the same conditions for comparison (dioptric range ~0.75 to 1 D). **c** Cylinder defocus curves demonstrating IC-8 ability to tolerate up to 1.5 D of uncorrected astigmatism without a line loss in visual acuity (VA). Data courtesy of Dr. Robert Ang



range of vision provided in their work as a truck driver. The advantage of the pin hole design in the treatment of irregular corneal astigmatism is also well documented with the XtraFocus pin hole IOL (Morcher, Stuttgart, Germany) [18–21]. The XtraFocus implant is a black, hydrophobic acrylic sulcus IOL that can be used in pseudophakic eyes, masks a greater area which may help with pupil abnormalities such as Aniridia and is translucent to infrared imaging. The

XtraFocus does not have any power and therefore is not a primary lens. In contrast, the IC-8 specifically corrects for spherical equivalent and utilises proprietary constructive and destructive interference in its mask to optimise the depth of focus.

The focus of our study was primarily on uncorrected visual acuity outcomes as well as spectacle independence following IC-8 IOL implantation. As the IC-8 does not

directly correct cylinder, MRSE rather than spherocylindrical refraction was used in pre-operative assessment of our patients (noting that eyes with more than 1.5 D of corneal cylinder were generally excluded) and manifest refraction was not evaluated post-operatively (a limitation of this study).

The patients with pre-existing ocular pathology achieved varying outcomes and their results were analysed separately. This was to minimise confounding of the outcomes in eyes with nothing more than cataract. Although all patients with ocular comorbidity achieved significant gain in extended depth of focus, as shown in Table 2b, the final results were hampered by their underlying pathology. Nonetheless each of these patients were satisfied with their surgical outcomes. The IC-8 proved to be particularly useful in cases of corneal scarring where the central visual axis is preserved, showing excellent outcomes post-operatively and one patient opting to have the implant bilaterally.

Our series included patients with pre-existing ocular comorbidities which would be considered relative contraindications for the implantation of multifocal IOLs. These include age-related macular degeneration, marked higher order aberrations from corneal pathology and epiretinal membranes. Though the number of such cases in our series is small, our patient experience suggests that patients who would otherwise be considered unsuitable for multifocal IOL implantation may well be considered suitable for the IC-8 lens.

Posterior capsule opacity

PCO was noted in 19 patients (6.6%). Due to the small aperture of the IC-8, PCO can have a profound impact on the visual acuity. Early uncertainty over the ability to perform YAG laser capsulotomy in eyes implanted with the IC-8 resulted in a number of explants at few centres. The procedure has been successfully performed in 10 patients in our cohort.

Managing patient expectations

Our approach in offering this IOL starts with the use of a pre-operative questionnaire to identify those patients seeking spectacle independence. In the patients opting for IC-8 implantation, it is important to educate them to the fact that their eyes will be made deliberately different. The intention is for the dominant eye to have optimised distance vision. The second, or non-dominant, eye is to have an extended range of vision. It is important that patients are made aware that if they 'test to compare' each eye they will notice differences—particularly when brightness measures are considered. This is as with any patient undergoing surgery with monofocal IOLs

in a monovision configuration—the vision in one eye will always be blurred at a particular distance. As with a 'multifocal' IOL, a period of adaptation is necessary before patients reap the full benefits of the IC-8 lens.

The role of IC-8 IOL is to improve functional near vision and reduce dependency on glasses following cataract surgery. A significant number of our patients without ocular comorbidity reported *complete* independence from glasses for near and distance visual performance following IC-8 IOL implantation. Patients rated their satisfaction with IC-8 on average 8.1 out of 10 for near vision and 9.1 out of 10 for distance vision. Only one patient (spontaneously) complained of experiencing glare in the early post-operative period, which settled by 6 weeks post-operatively. Further assessment of potential causes suggested a mesopic pupil size larger than that of the IC-8 IOL aperture (6 mm) might be contributory. Although the symptoms settled with time, the case highlighted the importance of mesopic pupil size in patient selection. We have subsequently taken into account pupil size for patient selection. Other symptoms experienced by patients as highlighted in the questionnaire mostly ranged from mild to moderate in severity (Table 1b). Unfortunately, the absence of baseline measurement of symptoms combined with a self-reported subjective scale make these results difficult to interpret. However, when patients were asked if they recommend the lens to friends and family, over 80% of the patients had no hesitation in recommending the IC-8.

Conclusions

The correction of presbyopia remains an important frontier of lens-based surgery. Loss of accommodation is considered by many to adversely affect quality of life. The IC-8 IOL is capable of providing an extended depth of focus following cataract surgery and allows spectacle independence in a majority of patients with unaided vision at near, intermediate and distance. Small aperture optics in IOLs is a promising technology with broader applications in correction of presbyopia in both phakic and pseudophakic eyes. The opportunities are bright for this technology, particularly if a sulcus-based IOL is developed for use in both phakic or pseudophakic patients.

Summary

What was known before

- IC-8 IOL in conjunction with a monofocal IOL in the fellow eye provides a continuous broad range of vision and excellent visual acuity across all focal distances.

What this study adds

- IC-8 IOL can be implanted in conjunction with other monofocal and multifocal IOLs. More than half of the patients implanted with the IC-8 IOL in one eye are capable of achieving complete independence from glasses for near and distance visual performance. Patients who would otherwise be considered unsuitable for multifocal IOL implantation due to pre-existing ocular pathology may well be considered suitable for the IC-8 lens. Optical image focus quality data for the IC-8 IOL and comparison with a monofocal IOL are provided for the first time.

Acknowledgements The authors would like to thank and acknowledge the contribution of Rachael Adams, Mitchell Bagley, Sandy Ly, Sara Skaf, Alison Gibson, David Holland and Peter Medon.

Compliance with ethical standards

Conflict of interest The authors declare that they have no conflict of interest.

Publisher's note: Springer Nature remains neutral with regard to jurisdictional claims in published maps and institutional affiliations.

References

- de Silva SR, Evans JR, Kirthi V, Ziaei M, Leyland M. Multifocal versus monofocal intraocular lenses after cataract extraction. *Cochrane Database Syst Rev.* 2016;12:Cd003169.
- Javitt JC, Steinert RF. Cataract extraction with multifocal intraocular lens implantation: a multinational clinical trial evaluating clinical, functional, and quality-of-life outcomes. *Ophthalmology.* 2000;107:2040–8.
- Leyland M, Zinicola E. Multifocal versus monofocal intraocular lenses in cataract surgery: a systematic review. *Ophthalmology.* 2003;110:1789–98.
- Gil MA, Varon C, Cardona G, Vega F, Buil JA. Comparison of far and near contrast sensitivity in patients symmetrically implanted with multifocal and monofocal IOLs. *Eur J Ophthalmol.* 2014;24:44–52.
- Gil MA, Varon C, Rosello N, Cardona G, Buil JA. Visual acuity, contrast sensitivity, subjective quality of vision, and quality of life with 4 different multifocal IOLs. *Eur J Ophthalmol.* 2012;22:175–87.
- Cumming JS, Slade SG, Chayet A. Clinical evaluation of the model AT-45 silicone accommodating intraocular lens: results of feasibility and the initial phase of a Food and Drug Administration clinical trial. *Ophthalmology.* 2001;108:2005–9. discussion 10.
- Dhital A, Spalton DJ, Gala KB. Comparison of near vision, intraocular lens movement, and depth of focus with accommodating and monofocal intraocular lenses. *J Cataract Refract Surg.* 2013;39:1872–8.
- Pepose JS, Burke J, Qazi MA. Benefits and barriers of accommodating intraocular lenses. *Curr Opin Ophthalmol.* 2017;28:3–8.
- Syedddain O, Riha W, Hohensinn M, Nix G, Dexl AK, Grabner G. Refractive surgical correction of presbyopia with the AcuFocus small aperture corneal inlay: two-year follow-up. *J Refract Surg.* 2010;26:707–15.
- Vilupuru S, Lin L, Pepose JS. Comparison of contrast sensitivity and through focus in small-aperture inlay, accommodating intraocular lens, or multifocal intraocular lens subjects. *Am J Ophthalmol.* 2015;160:150–62.e1.
- El-Husseiny M, Daas L, Viestenz A, Langenbucher BS. [The KAMRA inlay: a realistic approach]. *Ophthalmologie.* 2017;114:358–64.
- Igras E, O'Caomh R, O'Brien P, Power W. Long-term results of combined LASIK and monocular small-aperture corneal inlay implantation. *J Refract Surg.* 2016;32:379–84.
- Duignan ES, Farrell S, Treacy MP, Fulcher T, O'Brien P, Power W, et al. Corneal inlay implantation complicated by infectious keratitis. *Br J Ophthalmol.* 2016;100:269–73.
- Moshirfar M, Quist TS, Skanchy DF, Wallace RT, Linn SH, Hoopes PC. Six-month visual outcomes for the correction of presbyopia using a small-aperture corneal inlay: single-site experience. *Clin Ophthalmol.* 2016;10:2191–8.
- Grabner G, Ang RE, Vilupuru S. The small-aperture IC-8 intraocular lens: a new concept for added depth of focus in cataract patients. *Am J Ophthalmol.* 2015;160:1176–84.e1.
- Ong HS, Evans JR, Allan BD. Accommodative intraocular lens versus standard monofocal intraocular lens implantation in cataract surgery. *Cochrane Database Syst Rev.* 2014;5:Cd009667.
- Dick HB, Piovella M, Vukich J, Vilupuru S, Lin L. Prospective multicenter trial of a small-aperture intraocular lens in cataract surgery. *J Cataract Refract Surg.* 2017;43:956–68.
- Trindade BLC, Trindade FC, Trindade CLC, Santhiago MR. Phacoemulsification with intraocular pinhole implantation associated with Descemet membrane endothelial keratoplasty to treat failed full-thickness graft with dense cataract. *J Cataract Refract Surg.* 2018;44:1280–3.
- Tsaousis KT, Werner L, Trindade CLC, Guan J, Li J, Reiter N. Assessment of a novel pinhole supplementary implant for sulcus fixation in pseudophakic cadaver eyes. *Eye (Lond).* 2018;32:637–45.
- Trindade CC, Trindade BC, Trindade FC, Werner L, Osher R, Santhiago MR. New pinhole sulcus implant for the correction of irregular corneal astigmatism. *J Cataract Refract Surg.* 2017;43:1297–306.
- Trindade CLC, Trindade BLC. Novel pinhole intraocular implant for the treatment of irregular corneal astigmatism and severe light sensitivity after penetrating keratoplasty. *JCRS Online Case Rep.* 2015;3:4–7.