



# Infographic: residual intraretinal edema after 25-gauge vitrectomy and macular pucker removal: Is intraoperative sustained-release dexamethasone a real treatment option?

M. Al-Zubaidy <sup>1</sup> · A. Ghareeb<sup>1</sup> · I. Mostafa<sup>1</sup> · A. Mehta <sup>1</sup> · D. Murphy <sup>1</sup> · S. Sadiq<sup>1</sup> · A. Song <sup>1</sup> · N. Tzoumas<sup>1</sup> · D. H. Steel <sup>1</sup>

Received: 21 March 2021 / Revised: 26 March 2021 / Accepted: 31 March 2021 / Published online: 10 May 2021

© The Author(s) 2021. This article is published with open access

## Reference to original study:

Guidi G, Casini G, Ripandelli G, Piaggi P, Lucche FD, Sartini M, Loiudice P, Nasini F, Stripe M, Lazzeri S. Residual intraretinal edema after 25-gauge vitrectomy and macular pucker removal: Is intraoperative sustained-release dexamethasone a real treatment option? *Retina*. 2018;38:993–9. <https://doi.org/10.1097/IAE.0000000000001627>.

## Compliance with ethical standards

**Conflict of interest** The authors declare no competing interests.

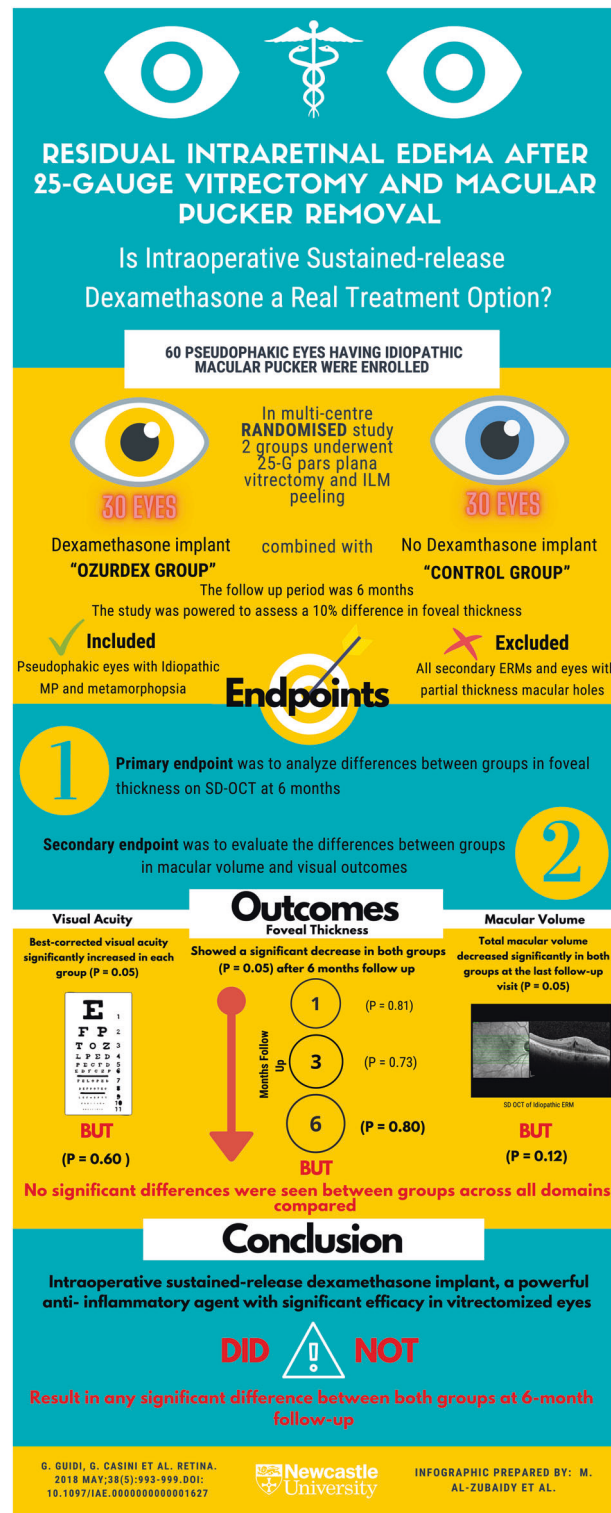
**Publisher's note** Springer Nature remains neutral with regard to jurisdictional claims in published maps and institutional affiliations.

**Open Access** This article is licensed under a Creative Commons Attribution 4.0 International License, which permits use, sharing, adaptation, distribution and reproduction in any medium or format, as long as you give appropriate credit to the original author(s) and the source, provide a link to the Creative Commons license, and indicate if changes were made. The images or other third party material in this article are included in the article's Creative Commons license, unless indicated otherwise in a credit line to the material. If material is not included in the article's Creative Commons license and your intended use is not permitted by statutory regulation or exceeds the permitted use, you will need to obtain permission directly from the copyright holder. To view a copy of this license, visit <http://creativecommons.org/licenses/by/4.0/>.

---

✉ D. H. Steel  
david.steel@ncl.ac.uk

<sup>1</sup> Institute of Biosciences, Newcastle University, Newcastle upon Tyne, UK



**Fig. 1** An infographic looking at the efficacy of the use of intraoperative sustained-release dexamethasone in patients who underwent 25-gauge vitrectomy and macular pucker removal. This randomised controlled trial aimed to investigate the efficacy and safety of intraoperative slow-release dexamethasone implant in vitrectomy plus OZRUDEX implant vs. vitrectomy without OZRUDEX implant for the treatment of idiopathic macular pucker. It found that intraoperative sustained-release dexamethasone implant, a powerful anti-inflammatory agent with significant efficacy in vitrectomized eyes, did not result in a significant change in macular thickness and volume compared with the vitrectomy alone without dexamethasone implant at 6-month follow-up. ERM epiretinal membrane, MP macular pucker.